



FN14 mRNA Expression Correlates with an Increased Number of Veins during Angiogenesis in the Process of Liver Fibrosis

Elena I. Lebedeva¹, Andrei S. Babenka², Pelin Hastemir³, Anatoliy T. Shchastniy⁴,
Dmitry A. Zinovkin^{5*}, Md Zahidul Islam Pranjol³

1. Department of Histology, Vitebsk State Medical University, Vitebsk, Belarus.

2. Department of Bioorganic Chemistry, Belarussian State Medical University, Minsk, Belarus.

3. School of Life Sciences, University of Sussex, Brighton, UK.

4. Department of Hospital Surgery Vitebsk State Medical University, Vitebsk, Belarus.

5. Department of Pathology, Gomel State Medical University, Gomel, Belarus.

Article type: ABSTRACT

Original Article

In this study, we hypothesize that angiogenesis of special hepatic vessels such as sinusoid capillaries or veins is closely associated with increasing production of connective tissue in fibrogenesis. Thirty-six male Wistar rats were induced with hepatitis and cirrhosis of the liver using thioacetamide. The number of sinusoidal capillaries, veins, arteries and the area of connective tissue were counted and determined. Immunohistochemical study was performed on paraffin sections using monoclonal mouse anti-CD31. mRNA expression was determined using qPCR. We found a statistically significant reduction in the number of sinusoidal capillaries ($p < 0.0001$) and an increase in the number of interlobular veins ($p < 0.0001$) in the fibrosis and cirrhosis groups compared to the control group. There are no differences in the number of interlobular arteries ($p = 0.282$) in the three groups. In our analysis, we found that the expression (mRNA) of Fn14 correlated with the number of veins in liver fibrosis ($r = 0.44$, $p = 0.008$). Our data shows that modulation of veins angiogenesis during fibrosis in chronic liver diseases may play an important role in increasing pathological changes of the liver.

Received:

2022.08.23

Revised:

2023.07.08

Accepted:

2023.07.15

Keywords: Angiogenesis, fibrosis, cirrhosis, FN14, liver

Cite this article: Lebedeva E. FN14 mRNA Expression Correlates with an Increased Number of Veins during Angiogenesis in the Process of Liver Fibrosis. *International Journal of Molecular and Cellular Medicine*. 2022; 11(3):274-284. DOI: 10.22088/IJMCM.BUMS.11.4.274

***Corresponding Author:** Dmitry A. Zinovkin

Address: Department of Pathology, Gomel State Medical University, Gomel, Belarus.

E-mail: zinovkin_da@gsmu.by



© The Author(s).

Publisher: Babol University of Medical Sciences

This work is published as an open access article distributed under the terms of the Creative Commons Attribution 4.0 License (<http://creativecommons.org/licenses/by-nc/4>). Non-commercial uses of the work are permitted, provided the original work is properly cited.

Introduction

Progressive liver fibrosis leads to cirrhosis, liver failure, hepatocellular carcinoma and is a major public health problem. Each year, more than one million people die worldwide from viral hepatitis and about the same number from complications of cirrhosis [1]. However, the mechanisms controlling these phenotypic and functional changes in liver fibrosis remain to be fully understood [2]. Substantial progress in understanding of the molecular pathogenesis of liver fibrosis has occurred; nonetheless, the mechanisms of liver fibrosis have not yet been completely elucidated. Therefore, further research on liver fibrosis in terms of its molecular pathogenesis is essential for identifying more suitable targets for therapeutic interventions [3].

Pathological angiogenesis is a hallmark of cancer and various ischemic and inflammatory diseases in which hypoxia and inflammation are strong stimulus for angiogenesis and vascular remodeling [2]. Hypoxia and inflammation are the most important elements resulting in liver fibrosis. Angiogenesis is another factor that plays an important role in the progression from liver fibrosis to cirrhosis [4]. However, at present, there is no explicit data available on the different types of vessels (capillaries, arteries or veins) and their role in the pathogenic process from fibrosis to cirrhosis.

The development of new functional vessels is closely related to precise orchestration of the molecular effectors that stimulate different processes. It comprehends consecutive phases and a large spectrum of proangiogenic mediators such as vascular endothelial growth factor (VEGF) and angiogenin [5]. VEGF interacts with endothelial precursor cells such as angioblasts and induces differentiation into mature endothelial cells. Stimulated endothelial cells secrete several plasminogen activators and matrix metallic proteases degrade the vascular basement membranes of parental vessels, aiding endothelial cells to invade the surrounding matrix. The immature endothelial cells proliferate and migrate to new sites where the hypoxia and hyperplasia of endothelial cells are accelerated to form solid endothelial tubes [6]. Angiogenin stimulates blood vessels growth via interaction with endothelial and smooth muscle cells [7]. To enable this process, angiogenin provides ribonucleolytic activity and the ability for nuclear translocation with enhancement of ribosomal RNA transcription in endothelial cells [8].

Tumor necrosis factor-like weak inducer of apoptosis (TWEAK) belongs to the TNF superfamily and acts by binding to its receptor, fibroblast growth factor-inducible 14 (Fn14), thereby activating a variety of intracellular signal transduction pathways in various types of cells [9]. Fn14 in healthy tissues are up-regulated and specifically activated in a variety of inflammatory tissues, thereby triggering a wide range of parenchymal, stromal, and progenitor cells involved in proinflammatory responses, angiogenesis, cell growth and death, and fibrotic reactions [10]. TWEAK and Fn14 can regulate the fibrogenic response following liver injury, by activation of hepatic stellate cells [11].

Studying the interactions between angiogenesis and fibrosis severity in the pathological process of liver fibrosis will provide a new perspective in revealing the new possible targets in pathological mechanism of liver fibrosis [12]. In the current study, we hypothesize that angiogenesis occurs in selective components of

the hepatic vessels such as sinusoid capillaries or veins and is closely associated with increasing production and volume of connective tissue in fibrogenesis in liver diseases such as hepatitis and liver cirrhosis. We performed immunohistochemical studies and showed an association between liver fibrosis and angiogenesis. Moreover, using qPCR, we reported a differential expression of FN14 mRNA in our samples.

Materials and methods

Ethical statement

The experimental study was approved by the Commission on Bioethics and Humane Treatment of Laboratory Animals of the Vitebsk State Order of Friendship Medical University (Protocol №6 of 03.01.2019). All manipulations with the animals were carried out according to the recommendations of the Council of Europe Convention on the Protection of Vertebrate Animals used for experimental and other scientific purposes of 18.03.1986, EEC Council Directive of 24.11.1986 and recommendations of FELASA Working Group Report (1994-1996).

Animals

The experiment consisted of 36 sexually mature male Wistar rats weighing 190-210 g. The rats were kept in plastic-metal cages (6 animals in each) placed on racks in natural light, with free access to food and water. The bedding used was formed of pre-decontaminated sawdust. The temperature in the vivarium was maintained at 21-23°C and the air humidity was about 50%. All animals received a standard, balanced diet at a set time. The rats received drinking water *ad libidum*.

Experiment

The animals were randomly divided into 3 groups of 12. Group 1 and 2 rats were induced with toxic hepatitis and liver cirrhosis, respectively. Group 3 was treated as control. All manipulations on the animals were carried out at the same time of the day from 9 to 10 AM to avoid the influence of diurnal biorhythms. Hepatitis and liver cirrhosis were induced by freshly prepared thioacetamide (TAA) solution (Acros Organics, Belgium). This was injected into the stomach with a probe at a dose of 200 mg/kg animal weight twice a week 3 hours before feeding. The duration of hepatitis induction consisted of injections for up to 5 weeks. For inducing the liver cirrhosis, the animals received TAA for up to 13 weeks. Rats in the control group received a similar volume of sterile saline water without thioacetamide (Figure 1).

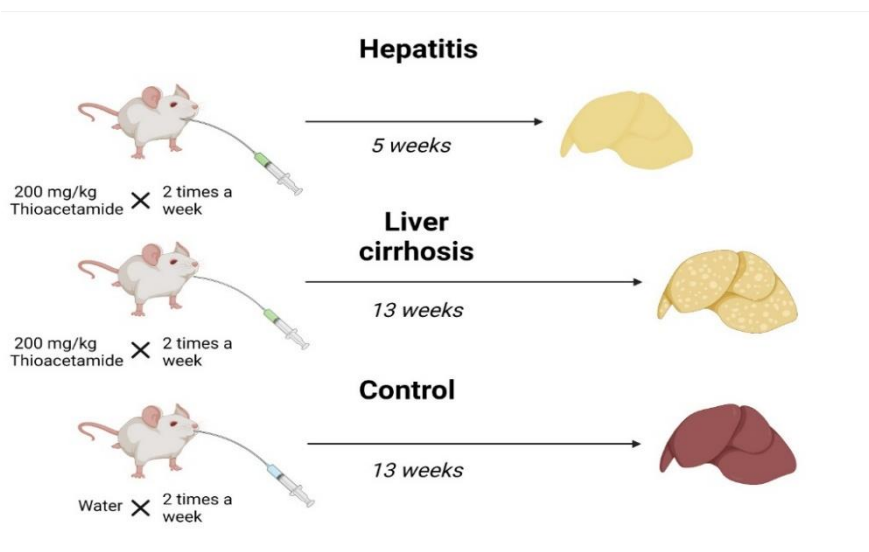


Fig.1. The scheme of the experiment.

The animals were humanely sacrificed in the experiment. Biological material was taken immediately after the death of the animal.

Isolation of total RNA and synthesis of cDNA

To determine the level of gene mRNA expression by real-time polymerase chain reaction (RT-PCR), fragments of an organ not larger than 5 mm in diameter were taken from the large left lobe of the rat's liver. After collection, the samples were placed in cryoprobes and then in liquid nitrogen (-195.75°C) for transportation and storage immediately before the RNA extraction procedure.

Extraction of total RNA was performed using ArtRNA MiniSpin reagent kit (ArtBioTech LLC, Belarus) according to the manufacturer's protocol. The samples were homogenized using porcelain mortars and pestles in the presence of liquid nitrogen without allowing the samples to thaw.

The cDNA was synthesized using oligo dT primers and ArtMMLV Total reagent kit (ArtBioTech LLC, Belarus) according to the manufacturer's instructions. The amount of total RNA of 200 ng/reaction was used for one reaction.

Design of oligonucleotide primers to estimate mRNA levels of target genes

Primer design was performed using the free online application Primer3 v. 0.4.0 (<http://bioinfo.ut.ee/primer3-0.4.0/>). The oligonucleotide sequences are presented in Table 1.

Table 1. Sequences of specific oligonucleotide primers and fluorescence-labelled probes.

Name of the oligonucleotide	The oligonucleotide sequence 5' → 3'	Label 5'	Label 3'
angF	TGCGAAAGTATGATGAGGAGAA		
angR	TGTTGCCATGGATAAAGGTG		
angP	ACCTCGCCCTGCAAAGAGGT	FAM	BHQ1
vegfaF	GCAGATCATGCGGATCAAA		
vegfaR	ATGCTGCAGGAAGCTCATCT		
vegfaP	CCTCACCAAAGCCAGCACAT	FAM	BHQ1
fn14F	GGATGCGCAGCAGCAC		
fn14R	CAAAACCAGGGCCAGACTAA		
fn14P	CCTGCCCACTTCAGGATGCT	FAM	BHQ1
hes1F	GAAAGATAGCTCCCCGGCATT		
hes1R	CGGAGGTGCTTCACTGTCAT		
hes1P	CCAAGCTGGAGAAGGCAGACA	FAM	BHQ1

RT-PCR

Reagents manufactured by Primetech, Belarus were used for RT-PCR. The final volume of reaction mixture was 25 µl and contained all components in the following concentrations: 2 mM magnesium chloride, 0.1 mM deoxynucleotide triphosphate mixture, 500 nM oligonucleotides including RT-PCR probe, 1.25 units of thermostable Taq DNA polymerase with appropriate buffer solution.

Mode of thermocycling: +95 °C- 2 min, then 40 cycles: +95 °C- 5 sec, +60 °C- 45 sec. FAM labeled probe was detected after each cycle. The PCR was carried out using BioRad equipment (CFX96touch, USA).

Normalization of RT-PCR data

Hes1 was used as a reference gene for normalizing RT-PCR data. The mRNA level of this gene in the preliminary study showed no response to experimental exposure throughout the whole period of observation, and the variation of its mRNA level within one experiment from animal to animal varied within 1 cycle.

Mallory`s Trichrome Stain

Rat liver tissue sections (5 µm) were prepared and stained with Masson's trichrome using standard histological techniques. Briefly, histopathological slides were deparaffinize and rehydrated. Next, the slides were stained by Weiget`s hematoxylin, Biebrich scarlet-acid fuchsin solution and differentiated in phosphomolybdic-phosphotungstic acid. The slides were then dehydrated in alcohol and mounted with resinous mounting medium [12].

Immunohistochemistry

Primary antibodies used in this study include the following: monoclonal mouse anti-CD31 (clone 9A9A4; 1:500; Elabscience, Wuhan, China) and polyclonal rabbit anti. 2-step plus Poly-HRP Anti Rabbit/Mouse IgG Detection System/with DAB Solution (Elabscience, Wuhan, China) was used for primary antibodies visualization.

Rat liver tissue sections were prepared, cut into 3-4 µm sections after that deparaffinization, heat antigen retrieval, washing, blocking with 3% BSA for 10 minutes and incubated with primary antibodies. Then primary antibodies were detected by the secondary antibody and visualized by DAB [13].

Morphometrical analysis

The measurements were carried out on digital images obtained with a digital camera Olympus XC30 (Olympus, Japan) based on a microscope Olympus BX51 (Olympus, Japan) at a magnification of ×400 in 3 non-overlapping fields of view on each histological section were analyzed.

Morphometric analysis was performed using Aperio ImageScope (Leica, Germany) and CellSens Software (Olympus, Japan) image analysis. The degree of fibrosis was determined according to the semi-quantitative Ishak K.G. scale and area of fibrosis presented as a percentage of fibrous tissue to all tissue in field of view [14]. The number of sinusoidal capillaries, veins and arteries was counted separately in each HPF. Then number of each type of vessels were converted in number in 1mm² by this formula:

$$N = \frac{\bar{X} n \times 1000000}{S}$$

Where, N is number of vessels in 1 mm²; X- is mean of number of vessels in HPF; and S is area of one high power field (HPF) ×400 (µ²). In this study S was equal 304000 µ².

Statistical analysis

All data were presented by the median, lower and upper quartiles. Kruskal-Wallis test was used for comparing the study groups based on the evaluated criteria. Dunn`s test was used for post hoc analysis. Spearman (r)

test was used to determine the correlations between studied parameters. A $p < 0.05$ was considered statistically significant. GraphPad Prism v. 9.0 was used for statistical analysis.

Results

In our experiments, we compared three parameters (area of fibrous tissue, number of vessels, and mRNA expressions) between three groups- control, hepatitis and cirrhosis.

Area of fibrous tissue was measured in diseased tissue sections

In the control liver section, a central vein was clearly visible in the center of the classic lobule (figure 2A) with the hepatic triads which consists of an interfollicular artery, an interfollicular vein and one or two interfollicular bile ducts in the periphery. The degree of fibrosis according to the Ishak K.G. scale was F0. Median of the area of fibrous tissue was 1.5% (1.00; 2.00%).

Group of animals with hepatitis demonstrated bridging fibrosis which was predominantly present in the parenchyma, characterized by the formation of fibrous tissue septa between the vessels of portal zones of the liver (Figure 2B). In addition to the complete septa, there were incomplete septa that began at portal zones and blindly ended in the parenchyma. Perihepatocellular fibrosis was observed in some areas. Fibrous tissue was clearly visible from the portal zones towards the center of the liver lobules, surrounding each hepatocyte. Hepatocytes surrounded by fibrotic tissue underwent atrophy. At this term of the experiment, the amount of fibrous tissue around the portal zones increased. The degree of fibrosis on the Ishak K.G. scale corresponded to F3/F4. The median of area of the fibrous tissue was 4.00 (2.25; 6.75%).

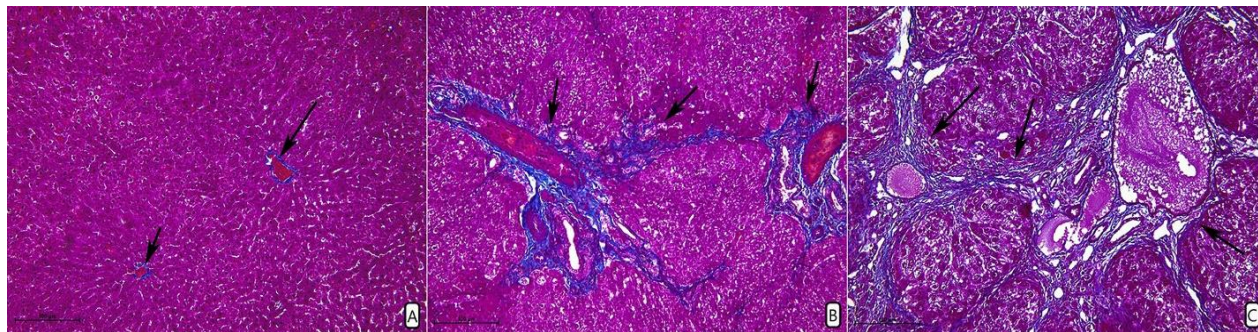


Fig.2. Histopathological changes of liver structure in: A – control group; B – group with hepatitis; C – group with liver cirrhosis. Black arrows indicate areas of the blue stained fibrous tissue. Stain: Trichrome Masson's stain. Magnification: $\times 100$

Histological examination of the group with cirrhotic liver revealed a total lesion of the parenchyma in the form of replacement by fibrous tissue in the areas of vacuole dystrophy (Figure 2C). The observed cirrhosis with extensive fields of fibrous tissue revealed pseudoliver lobules of various sizes, mainly of round shape. In some places of the histological sections fibrous tissue septa from portal areas penetrated as interlayers of fibrous tissue into the center of large false liver lobules with their subsequent segmentation. More than 30 cross-sections of the bile ducts were detected in individual portal areas (ductular reaction). The degree of fibrosis according to the Ishak K.G. scale was F6. The median of area of fibrous tissue was 13.50% (11.25; 17.50%).

Kruskal-Wallis test (Figure 3A) revealed statistically significant differences ($p < 0.0001$). Pos-hoc Dunn's test showed statistically significant differences between the areas of fibrous tissue in control and group of cirrhosis ($p < 0.0001$), and between the groups with hepatitis and cirrhosis ($p = 0.0037$).

Increase in the number of vein in liver fibrosis

In the control group, sinusoidal capillaries thickly permeated liver parenchyma, small number of arteries and veins were found in stromal compartment. In cases with hepatitis, a decrease in the number of sinusoidal capillaries was observed in the liver parenchyma. A similar observation was found in the liver stroma of the control group histotopography of the veins and arteries. Cirrhotic liver microscopically has manifested a reduction in the number sinusoidal capillaries whereas the number of arteries remained the same as in previous groups. However, in large areas of fibrous tissue, groups of dilatated veins could be observed (Figure 3H).

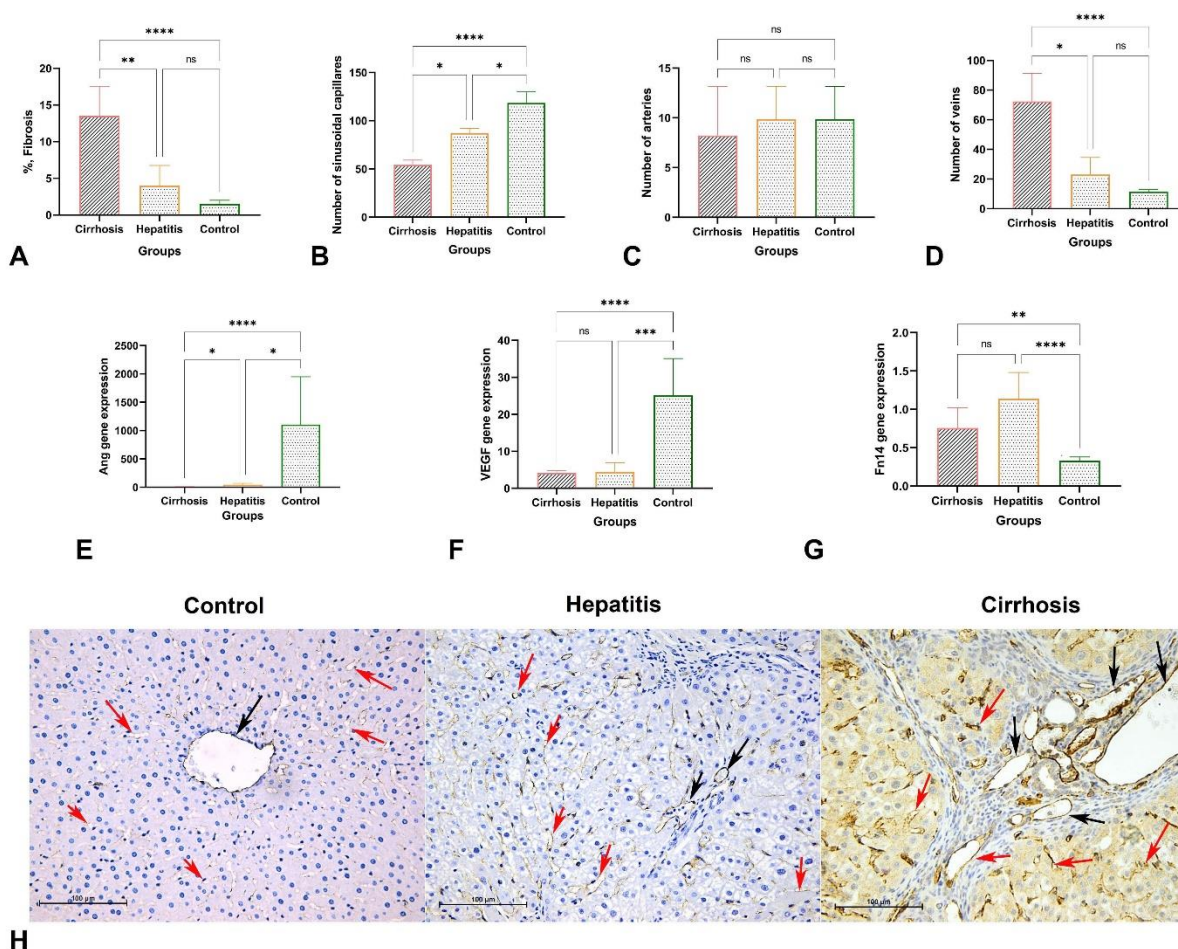


Fig.3. Kruskal-Wallis test results for area of fibrosis (A), number of capillaries (B), arteries (C), veins (D); Comparison of Ang (E), VEGF (F) and Fn14 (G) gene expression. Predominantly periportal CD31 expression by endothelial cells in control group, expression of CD31 by endothelial cells of sinusoid capillaries in the group with hepatitis, a network of sinusoid capillaries in the liver parenchyma and big group of veins in fibrous tissue in group with liver cirrhosis; Black arrows indicate the veins, red – sinusoidal capillaries. Magnification: $\times 200$, (H).

The number of sinusoidal capillaries in the control, hepatitis and cirrhosis groups were 118.4 (107.7; 129.9) per 1 mm², 87.2 (82.2; 92.1) per 1 mm² and 54.3 (42.8; 59.2) per 1 mm², respectively. A comparison between the three groups showed statistically significant differences (Figure 3B) in the number of sinusoidal capillaries per 1 mm² ($p < 0.0001$). Post-hoc test also revealed statistically significant differences in the number of sinusoidal capillaries per 1 mm² expression between the control and group of cirrhosis ($p < 0.0001$); group of animals with hepatitis and control ($p = 0.0157$); group of animals with hepatitis and group of cirrhosis ($p = 0.0157$).

The number of arteries per 1 mm² in various groups was as follows: control group - 9.8 (9.8; 13.6), hepatitis group - 9.8 (7.4; 13.2) and cirrhosis group - 8.2 (6.6; 13.2). Comparing the groups did not reveal statistically significant differences (Figure 3C) in the number of the interlobular arteries ($p = 0.282$). The number of veins per 1 mm² in control, hepatitis and cirrhosis groups were 11.5 (9.8; 16.6), 23.0 (17.3; 34.5) and 72.4 (53.5; 91.3), respectively. Statistically significant differences (Figure 3D) in the number of veins ($p < 0.0001$) were determined. Dunn's post-hoc test revealed statistically significant differences in the number of veins per 1 mm² between the control and cirrhosis groups ($p < 0.0001$), and animals with hepatitis and cirrhosis ($p = 0.0107$).

Significant increase in mRNA expressions of VEGF, Ang and Fn14

Ang gene expression in control group was 1108 (765.9; 1952.0), hepatitis group - 43.35 (25.93; 69.55) and cirrhosis group - 11.7 (9.9; 15, 5). A Kruskal-Wallis test revealed statistically significant differences (Figure 3E) in Ang expression ($p < 0.0001$). Post-hoc test revealed statistically significant differences in Ang gene expression between control and cirrhosis ($p < 0.0001$) groups; control and hepatitis ($p = 0.0124$) groups; hepatitis and cirrhosis ($p = 0.0252$) groups.

VEGF gene expression in control, hepatitis and cirrhosis groups were 25.15 (17.10; 35.08), 4.45 (2.77; 6.93), 4.15 (3.17; 4.82) respectively. A comparison between the three groups showed statistically significant differences (Figure 3F) in VEGF expression ($p < 0.0001$). Post-hoc test also revealed statistically significant differences in VEGF expression between control and group of cirrhosis ($p < 0.0001$); group of animals with hepatitis and control ($p < 0.0001$).

Fn14 gene expression in control, hepatitis and cirrhosis groups were 0.32 (0.08; 0.37), 1.13 (1.02; 0.37) and 0.75 (0.65; 1.02). A statistically significant differences (Figure 3G) in Fn14 gene expression were found ($p < 0.0001$). Post-hoc test also revealed statistically significant differences in Fn14 gene expression between control and group of cirrhosis ($p = 0.0042$); group of animals with hepatitis and control ($p < 0.0001$).

Correlation analysis.

The correlations between the parameters are shown in figure 4. There was a strong positive correlation between Ang and VEGF genes ($r = 0.80$, $p < 0.0001$). Additionally, strong positive correlations were found between Ang gene and number of sinusoidal capillaries ($r = 0.80$, $p < 0.0001$), and VEGF gene and number of sinusoidal capillaries ($r = 0.72$, $p < 0.0001$).

Moderate positive correlations were determined between area of the fibrous tissue and number of veins ($r = 0.68$, $p < 0.0001$). Weak positive correlations were observed between Fn14 gene expression and number of veins ($r = 0.44$, $p = 0.008$).

Strong negative correlations were revealed between: Ang gene and number of veins ($r=-0.84$, $p<0.0001$), Ang gene and area of fibrous tissue ($r=-0.74$, $p<0.0001$), VEGF gene and number of veins ($r=-0.70$, $p<0.0001$), Fn14 gene and VEGF gene ($r=-0.75$, $p<0.0001$).

Moderate inverse correlations were present between Ang gene and Fn14 gene ($r=-0.55$, $p=0.0005$), number of capillaries and Fn14 gene ($r=-0.53$, $p=0.001$).

Weak negative correlation was observed between VEGF gene expression and area of fibrous tissue ($r=-0.44$, $p=0.006$).

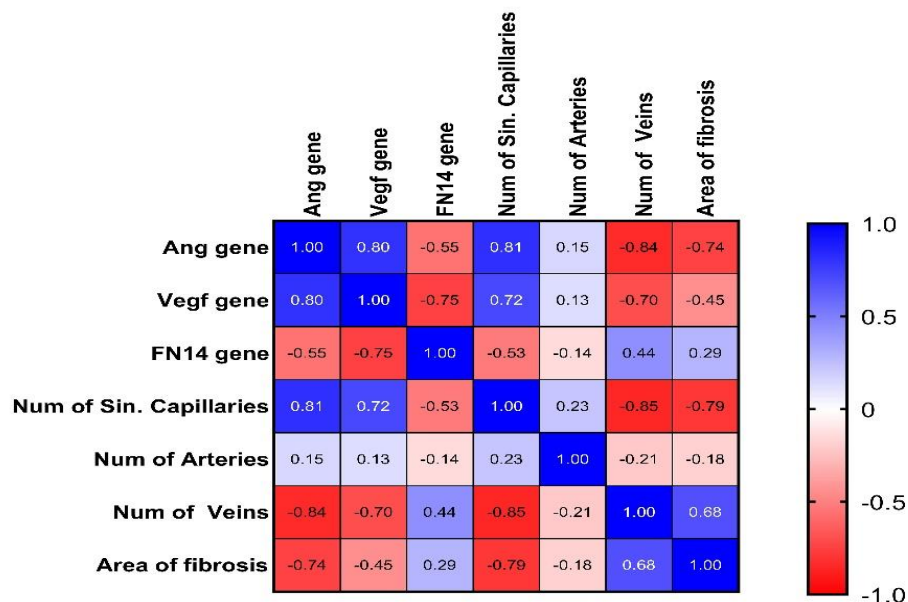


Fig.4. A correlation plot showing an association between the groups shown on the figure. Ang gene – Ang gene mRNA expression; Vegf gene – VEGF gene mRNA expression; FN14 gene – Fn14 gene mRNA expression; Num of Sin. Capillaries – number of sinusoidal capillaries per 1mm²; Num of Arteries – number of sinusoidal capillaries per 1mm²; Num of Veins – number of veins per 1mm²; Area of fibrosis – area of the fibrous tissue.

Discussion

Angiogenesis in the process of liver injury can be an active contributor to the production of a fibrotic environment during fibrogenesis by synthesis of collagen and fibronectin, especially during liver cirrhosis development [15]. Several studies revealed an increase in liver micro vessels in the progression of hepatitis and cirrhosis [16], and unlike our study, other authors counted numbers of all types of micro vessels [17, 5, 18]. In our study, we revealed a statistically significant reduction in the number of sinusoidal capillaries in the cirrhosis group versus the control group. A decrease in this type of vessels is associated with a depletion of hepatocyte volume (where sinusoidal capillaries are situated), and an increase in fibrous tissue compartment in liver which is specific for such conditions as hepatitis and liver cirrhosis [19]. There is significant evidence suggesting that the increase in portal blood flow in chronic liver injury accompanied by fibrosis is due not only to splanchnic vasodilation but also to an enlargement of the splanchnic vascular tree caused by angiogenesis [20]. We suggest that an increase in the number of veins is associated with

angiogenesis of collateral vessels, which are “pathological” because they further increase portal vein inflow and increase the portal pressure [21].

Ang and VEGF stimulate micro vessel growth via interaction with endothelial and smooth muscle cells [22]. Hepatocytes are the main cells producing VEGF and Ang in the liver. Mechanisms and activity of VEGF and Ang are decreased in hepatitis and liver cirrhosis, described by Serrano S.A. *et al.* (2019), could be associated with a reduction of expression of these genes due to endothelial dysfunction related to portal hypertension [23]. This could explain the demonstrated statistically significant reduction of Ang and VEGF expression in groups of animals with hepatitis and cirrhosis. Several studies have reported an increased Ang and VEGF mRNA expression [24; 25; 26; 27], where authors observed different subtypes of the VEGF and Ang mRNA expression. In our study, we measured the total mRNA expression of these markers [22]. Fn14 expression is rapidly up-regulated following liver injury and is associated with liver progenitor cells [10]. The Fn14 level is relatively low in resting primary hepatic stellate cells and is significantly induced in activated hepatic stellate cells, which further enhances the effect of TGF- β [18]. In the carbon tetrachloride-induced murine model of acute and chronic liver injury, the expression of the Fn14 gene was up-regulated [27]. This could explain the observed statistically significant increase in the Fn14 mRNA expression in groups of hepatitis and cirrhosis.

Strong positive correlation between VEGF and Ang revealed could be associated with the similar functions of these genes which focused on angiogenesis and vessels maturation and remodeling in chronic liver diseases [28]. Furthermore, proangiogenic function of these two genes explains its strong correlations with number of sinusoidal capillaries [5].

An increase of liver fibrosis causes deregulation of the hepatic hemodynamics and correlates positively with portal hypertension. They enhanced the portal pressure favoring hypercontractility state, leading to increased intrahepatic vascular resistance, decreased liver perfusion and activation of angiogenesis [29]. It could explain the moderate correlations between area of the fibrosis and number of veins.

Weak positive correlation between Fn14 and number of the veins could be explained by the role of Fn14 gene in process of angiogenesis and fibrosis due to the inflammation in process of the chronic liver injury [30].

In chronic liver injury TWEAK secreted from macrophages, monocytes, and T lymphocytes upon liver injury through activation of the Fn14 activate liver-resident progenitor cells which drive fundamental repair mechanisms, such as neo-angiogenesis [1, 32]. Negative correlations between Ang and Fn14, VEGF and Fn14, VEGF and number of the veins revealed in our study could be associated with a reduction of an increase in the stromal compartment by enhancing the activity of fibrogenesis in the development of hepatitis and cirrhosis [33]. It is known that Ang and VEGF are secreted predominantly by parenchyma of the liver, but this compartment volume is decreasing in the process of cirrhosis development [34]. Simultaneously, the increase of fibrosis and hypoxia of the stroma cause the increase of angiogenesis and expression of Fn14 [35]. Studies have found that the number of new blood vessels in the liver is directly proportional to the degree of liver fibrosis and inversely proportional to the reversibility of liver fibrosis [36, 37]. The present study provides further evidence that fibrosis is associated with neoangiogenesis. But in our study, we observed that in case of hepatitis and liver cirrhosis, there is significant increase in the number of veins. We

suggest that this process was regulated by Fn14 mRNA expression and therefore, our data could be used for the development of new therapeutic strategies.

This study revealed close associations between an increase in liver fibrosis and predominantly venous angiogenesis. Our data shows that modulation of veins angiogenesis during fibrosis in chronic liver diseases could play one of the key roles in increasing pathological changes in liver. Furthermore, Fn14 mRNA expression and its positive correlation with venous angiogenesis indicated a transcriptional role in this process. Our data could be useful for the determination of the new methods of the diagnostics and treatment of the chronic liver diseases.

References

1. Zhai M, Long J, Liu S, et al. The burden of liver cirrhosis and underlying etiologies: results from the global burden of disease study 2017. *Aging (Albany NY)* 2021;13:279-300.
2. Roehlen N, Crouchet E, Baumert TF. Liver Fibrosis: Mechanistic Concepts and Therapeutic Perspectives. *Cells* 2020;9.
3. Delgado ME, Cardenas BI, Farran N, et al. Metabolic Reprogramming of Liver Fibrosis. *Cells* 2021;10.
4. Li H. Angiogenesis in the progression from liver fibrosis to cirrhosis and hepatocellular carcinoma. *Expert Rev Gastroenterol Hepatol* 2021;15:217-33.
5. Elpek GO. Angiogenesis and liver fibrosis. *World J Hepatol* 2015;7:377-91.
6. Park S, Kim JW, Kim JH, et al. Differential Roles of Angiogenesis in the Induction of Fibrogenesis and the Resolution of Fibrosis in Liver. *Biol Pharm Bull* 2015;38:980-5.
7. Zhang H, Gao X, Weng C, et al. Interaction between angiogenin and fibulin 1: evidence and implication. *Acta Biochim Biophys Sin (Shanghai)* 2008;40:375-80.
8. Queck A, Uschner FE, Ferstl PG, et al. Role of circulating angiogenin levels in portal hypertension and TIPS. *PLoS One* 2021;16:e0256473.
9. Mendez-Barbero N, Gutierrez-Munoz C, Blazquez-Serra R, et al. Tumor Necrosis Factor-Like Weak Inducer of Apoptosis (TWEAK)/Fibroblast Growth Factor-Inducible 14 (Fn14) Axis in Cardiovascular Diseases: Progress and Challenges. *Cells* 2020;9.
10. Wilhelm A, Shepherd EL, Amatucci A, et al. Interaction of TWEAK with Fn14 leads to the progression of fibrotic liver disease by directly modulating hepatic stellate cell proliferation. *J Pathol* 2016;239:109-21.
11. Shi H, Dong L, Bai Y, et al. Chlorogenic acid against carbon tetrachloride-induced liver fibrosis in rats. *Eur J Pharmacol* 2009;623:119-24.
12. Chen L, Brigstock DR. Analysis of Pathological Activities of CCN Proteins in Fibrotic Diseases: Liver Fibrosis. *Methods Mol Biol* 2017;1489:445-63.
13. Ling L, Li G, Meng D, et al. Carvedilol Ameliorates Intrahepatic Angiogenesis, Sinusoidal Remodeling and Portal Pressure in Cirrhotic Rats. *Med Sci Monit* 2018;24:8290-7.
14. Lo RC, Kim H. Histopathological evaluation of liver fibrosis and cirrhosis regression. *Clin Mol Hepatol* 2017;23:302-7.
15. Acharya P, Chouhan K, Weiskirchen S, et al. Cellular Mechanisms of Liver Fibrosis. *Front Pharmacol* 2021;12:671640.
16. Gana JC, Serrano CA, Ling SC. Angiogenesis and portal-systemic collaterals in portal hypertension. *Ann Hepatol* 2016;15:303-13.
17. Zadorozhna M, Di Gioia S, Conese M, et al. Neovascularization is a key feature of liver fibrosis progression: anti-angiogenesis as an innovative way of liver fibrosis treatment. *Mol Biol Rep* 2020;47:2279-88.

18. Dhar D, Baglieri J, Kisseleva T, et al. Mechanisms of liver fibrosis and its role in liver cancer. *Exp Biol Med* (Maywood) 2020;245:96-108.
19. Gandhi C, Pinzani M. *Stellate cells in health and disease*: Academic Press; 2015.
20. Tugues S, Fernandez-Varo G, Munoz-Luque J, et al. Antiangiogenic treatment with sunitinib ameliorates inflammatory infiltrate, fibrosis, and portal pressure in cirrhotic rats. *Hepatology* 2007;46:1919-26.
21. Iwakiri Y, Trebicka J. Portal hypertension in cirrhosis: Pathophysiological mechanisms and therapy. *JHEP Rep* 2021;3:100316.
22. Novo E, Cannito S, Zamara E, et al. Proangiogenic cytokines as hypoxia-dependent factors stimulating migration of human hepatic stellate cells. *Am J Pathol* 2007;170:1942-53.
23. Serrano CA, Ling SC, Verdaguer S, et al. Portal Angiogenesis in Chronic Liver Disease Patients Correlates with Portal Pressure and Collateral Formation. *Dig Dis* 2019;37:498-508.
24. Cai J, Hu M, Chen Z, et al. The roles and mechanisms of hypoxia in liver fibrosis. *J Transl Med* 2021;19:186.
25. Yoo HHB, Marin FL. Treating Inflammation Associated with Pulmonary Hypertension: An Overview of the Literature. *Int J Gen Med* 2022;15:1075-83.
26. Leake I. Liver: Does angiogenesis have a role in the resolution of liver fibrosis? *Nat Rev Gastroenterol Hepatol* 2015;12:63.
27. Zhang Y, Zeng W, Xia Y. TWEAK/Fn14 axis is an important player in fibrosis. *J Cell Physiol* 2021;236:3304-16.
28. Bocca C, Novo E, Miglietta A, et al. Angiogenesis and Fibrogenesis in Chronic Liver Diseases. *Cell Mol Gastroenterol Hepatol* 2015;1:477-88.
29. Tripathi DM, Hassan M, Siddiqui H, et al. Cirrhotic Endothelial Progenitor Cells Enhance Liver Angiogenesis and Fibrosis and Aggravate Portal Hypertension in Bile Duct-Ligated Cirrhotic Rats. *Front Physiol* 2020;11:617.
30. Karaca G, Swiderska-Syn M, Xie G, et al. TWEAK/Fn14 signaling is required for liver regeneration after partial hepatectomy in mice. *PLoS One* 2014;9:e83987.
31. Higashi T, Friedman SL, Hoshida Y. Hepatic stellate cells as key target in liver fibrosis. *Adv Drug Deliv Rev* 2017;121:27-42.
32. Kaur S, Siddiqui H, Bhat MH. Hepatic Progenitor Cells in Action: Liver Regeneration or Fibrosis? *Am J Pathol* 2015;185:2342-50.
33. Khanam A, Saleeb PG, Kottilil S. Pathophysiology and Treatment Options for Hepatic Fibrosis: Can It Be Completely Cured? *Cells* 2021;10.
34. Caligiuri A, Gentilini A, Pastore M, et al. Cellular and Molecular Mechanisms Underlying Liver Fibrosis Regression. *Cells* 2021;10.
35. Gomez IG, Roach AM, Nakagawa N, et al. TWEAK-Fn14 Signaling Activates Myofibroblasts to Drive Progression of Fibrotic Kidney Disease. *J Am Soc Nephrol* 2016;27:3639-52.
36. Luo N, Li J, Wei Y, et al. Hepatic Stellate Cell: A Double-Edged Sword in the Liver. *Physiol Res* 2021;70:821-9.
37. Lafoz E, Ruat M, Anton A, et al. The Endothelium as a Driver of Liver Fibrosis and Regeneration. *Cells* 2020;9.